Potential of Herbs as Clinical Photosensitizers

Eric Yarnell, ND, RH (AHG), and Kathy Abascal, BS, JD, RH (AHG)

Abstract

Combined with ultraviolet (UV) light exposure, *Ammi majus* (bishop's weed) and *Ammi visnaga* (khella) are two photosensitizing herbs containing furanocoumarins known since ancient times to be helpful for topical treatment of vitiligo. These herbs have also been shown to be helpful for treating psoriasis in a similar way. Modern psoralen plus UV treatment is based on these herbs. *Lomatium dissectum* (desert parsley), *Heracleum lanatum* (cow parsnip), and *Heracleum mantegazzianum* (hog parsnip) are other members of the Apiaceae family known to be photosensitizing that may be developed for medicinal use in this manner.

Hypericum perforatum (St. John's wort), hypericin, and pseudohypericin are photoactivated by visible light. They have been assessed in many trials for both diagnosis of cancers (including those of the urinary bladder and brain) and, combined with laser light, treatment for several conditions (particularly urinary-bladder cancer, but also gliomas and macular degeneration). Rutaceae (citrus) family plants, such as *Ruta graveolens* (rue), *Ruta chalepensis* (fringed rue), *Citrus* x *paradisi* (grapefruit), *Citrus reticulata* (mandarin orange, *chen pi*), and *Citrus* x *hystrix* (kaffir lime), are also of potential interest as clinical photosensitizers.

Introduction

Ultraviolet (UV) light therapy is helpful for addressing numerous conditions. It continues to be a common treatment for psoriasis and vitiligo, two autoimmune skin diseases. There is a less-common use of UV light to treat infections of the skin and pharynx. Interest is also growing in the potential of using UV light to treat urinary-bladder, esophageal, and brain cancers. This article explores the use of herbs and herbal compounds to augment the efficacy and reduce the toxicity of UV phototherapy. In addition, coverage includes the use of herbs and herbal extracts to augment the efficacy of photodynamic diagnosis and therapy (i.e., use of visible light for diagnosis and treatment of various diseases).

There are two types of therapeutic UV light, A and B (see Fig. 1).[1] UV-A is long-wave, at 320–400 nm. UV-A1 is 340–400 nm and UV-A2 is 320–340 nm. UV-A makes up the majority of natural sunlight; chronic exposure to it is associated with photoaging and indirect carcinogenesis by formation of free radicals in the skin. UV-B is medium-wave, at 290–320 nm. In overdose, it can cause sunburn, photoaging, and cancer (through direct DNA damage). UV-B is also responsible for vitamin D activation. Narrowband UV-B has peak emission at 311 nm and a range of 310–315 nm. Conditions known to be amenable to phototherapy are reviewed in Table 1, but this review focuses on psoriasis, vitiligo, and various cancers.

Additional herbs and herbal constituents have a long history of use for augmenting phototherapy. Existing and potentially beneficial agents for this use are reviewed.

Psoralens

The internal use of furanocoumarin-containing plants to treat vitiligo is described in ancient medical texts from Egypt and India including the Ebers Papyrus (1550 BC) and Atharva Veda (1400 BC). *Ammi majus* (bishop's weed) and *Ammi visnaga* (khella) are two of the plants in the Apiaceae widely considered to have been used since ancient times as photosensitizers. These two members of the Apiaceae family are rich in furanocoumarins (also known as psoralens). The first modern trial reporting the efficacy of oral, topical, and combined oral/topical use of any furanocoumarin-containing herb and phototherapy for patients with vitiligo was in 1948 using bishop's weed.[2] Many other clinical reports verified these initial findings.[3–5]

Bishop's weed, native to the Mediterranean region (and an introduced weed in various tropical locations as well as the southern and central United States), contains 8-methoxypsoralen (methoxsalen; see Fig. 2). This furanocoumarin is now the most widely used oral and topical agent in conventional photochemotherapy. Bishop's weed contains other interesting

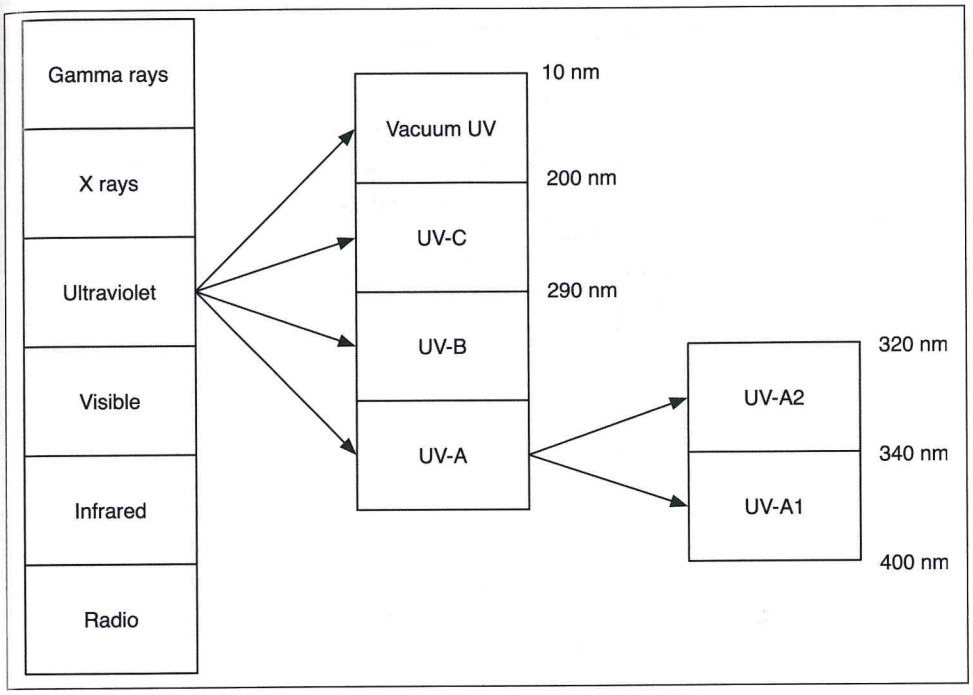

Figure 1. The electromagnetic spectrum (focusing on ultraviolet).

compounds. Furanocoumarins other than 8-methoxypsoralen have been shown to have inflammation-modulating effects in vitro.[6] A recent study in rodents suggests that bishop's weed seed tincture is inflammation-modulating in vivo, and improves lipid status as well as reducing pain and fever.[7] Bishop's weed also contains flavonoids, such as kaempferol, that are known to have beneficial effects.[8] Overdosing on bishop's weed has apparently been reported to cause a severe, widespread photodermatitis in one Moroccan woman with vitiligo.[9] This is a risk with all photosensitizing plants and medicines.

Khella is more well-known as a bronchodilator and coronary-artery spasmolytic that is useful for patients with asthma and angina.[10] This herb also contains furanocoumarins, notably khellin (see Fig. 2), that are photosensitizing. Oral khellin has proven to be effective in combination with natural sun exposure for treating psoriasis and vitiligo in various double-blinded clinical trials.[11,12] Khellin and phenylalanine mixed with phosphatidylcholine taken orally, combined with UV-A and -B phototherapy, led to significant and sustained improvement in patients with vitiligo, compared to phototherapy alone in one open trial.[13] However, in one randomized trial, a 2% khellin solution applied topically three times weekly with 90 minutes of sun exposure was no better than placebo with sun exposure in patients with vitiligo.[14]

Whole-plant extracts should be used clinically (applying an amount sufficient to cover the affected areas with a tincture or a tincture-saturated cream) with daily UV exposure of at least 30 minutes to achieve optimal outcomes.

Khellin has been shown to form an adduct with DNA, enhanced by the UV light.[15] This adduct has a modest ability to kill cells. This low-potency interaction and cytotoxic effect may help reduce adverse effects.[16] Pure 8-methoxypsoralen is clearly more potent but also carries with it a significant risk of skin cancers.[17]

Other Apiaceae family plants are known to induce photosensitivity rashes in some patients and, thus, may be able to be used as photosensitizers (because they may be usable at lower doses). *Lomatium dissectum* (desert parsley), *Heracleum lanatum* (cow parsnip), and *H. mantegazzianum* (hog parsnip or giant hogweed) are three well-known examples.[18,19] However, these herbs have not, to our knowledge, been recorded as being therapeutic in this way, and so their potential remains theoretical.

Hypericins

Hypericum perforatum (St. John's wort) contains several photoactive compounds known as hypericins, notably hypericin and pseudohypericin (see Fig. 3). These compounds have a reddish or purple color. They and the polar methanolic extract (PME) of St. John's wort fluoresce in the 550–650 nm range, which is yellow-to-orange visible light, regardless of pH.[20]

Internal use of high doses of St. John's wort can induce a photosensitive rash in some patients, although this is rare at therapeutic doses. Concern about this outcome was magnified by use of isolated intravenous (i.v.) hypericin, which did cause quite a bit of problem (at least in light-skinned patients with hepatitis C or HIV infection), although this is hardly relevant to oral use of crude extracts.[21,22] One study of healthy men found that oral St. John's wort extracts taken for 2 weeks at usual therapeutic doses had no predictable effect on photosensitivity.[23] Another study using very high oral doses found only a marginal increase in photosensitivity.[24]

Hypericin and PME have been shown to sensitize leukemia cells to laser light in vitro.[25] The same is true of bladder-cancer cells, and hyperforin and chlorophyll were clearly shown not to contribute significantly to this action.[26]

Instillation of 40 mL of an 8-μM solution of hypericin (a total of 160 mcg of hypericin) for 2 hours resulted in clear red fluorescence of cancerous lesions in the bladders of 40 patients with various types of bladder cancer or risks for it when exposed to a blue-light laser.[27] The mechanism underlying tumor avidity for hypericin is not known, but it appears that hypericin dissociates from serum lipoproteins in peritumor necrotic tissue and thus penetrates into surrounding neoplastic cells, according to one study.[28] Some of these patients had undergone radiation or bacillus Calmette-Guérin (BCG) therapy

Table 1. Conditions Amenable to Phototherapy

Condition	Phototherapies used
Psoriasis	PUVA, broadband UV-B, narrowband UV-B
Atopic dermatitis	UV-A1, broadband UV-B, narrowband UV-B, full-spectrum light
Vitiligo*	Psoralens + UV-A, narrowband UV-B
Scleroderma, localized (morphea)	UV-A1, PUVA
Mycosis fungoides (cutaneous T-cell lymphoma)	PUVA
Cutaneous mastocytosis	UV-A1
Dyshidrosis	UV-A1
Granuloma annulare	UV-A1, PUVA
Keloids	UV-A1
Sarcoidosis	UV-A1
Pityriasis lichenoides	UV-A1, narrowband UV-B
Systemic lupus erythematosus	UV-A1
Chronic urticaria	Narrowband UV-B
Granuloma annulare, generalized	Narrowband UV-B
Lichen planus	Narrowband UV-B
Lichen simplex, chronicus	Narrowband UV-B
Mastocytosis	Narrowband UV-B, PUVA
Pruritus	Narrowband UV-B
Seborrheic dermatitis	Narrowband UV-B
Alopecia areata	PUVA
Graft-versus-host disease, topical	PUVA
Dermatitis herpetiformis	PUVA with gluten-free diet
Dyshidrotic eczema	PUVA
Histiocystosis	PUVA
Urticaria	PUVA
Bladder cancer	Visible light + photosensitizers
Glioma	Visible light + photosensitizers

Adapted from: Walker D, Jacobs H. Phototherapy in the age of biologics. Semin Cutan Med Surg 2011;30:190–198.
*Hand and foot lesions cannot be treated effectively with phototherapy.
PUVA, oral or topical 8-methoxypsoralen + broadband ultraviolet–A; UV, ultraviolet.

for bladder cancer previously; assessing therapeutic efficacy was the goal in these patients.

Of 142 biopsies taken that showed carcinoma in situ, 132 fluoresced red after hypericin instillation under a blue-light laser (10 false-negatives, although 7 showed severe desquamation and so may have represented sufficient cell death caused by hypericin to preclude obtaining an adequate sample to assess neoplastic behavior). Of 139 biopsies that were negative, 2 fluoresced the same color as the true-positives (false-positives). Bacteria and radiation cystitis sites

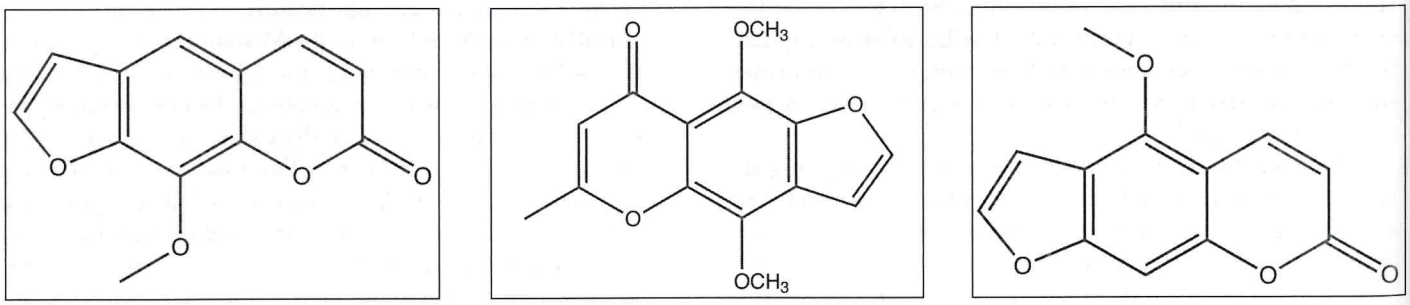

Figure 2. Furanocoumarin structures, including 8-methoxypsoralen (left), khellin (center), and bergapten (right).

did not cause false-positive results. This correlated to 93% sensitivity and 98% specificity. There were no adverse effects.

Compared to 5-aminolevulinic acid (5-ALA), currently in use for photodynamic diagnosis of bladder cancer, hypericin was stable for 16 hours after instillation (5-ALA disappears more rapidly), fluoresced continuously under blue light (5-ALA rapidly bleaches out), had far fewer false-positive and false-negative readings, and was safer.

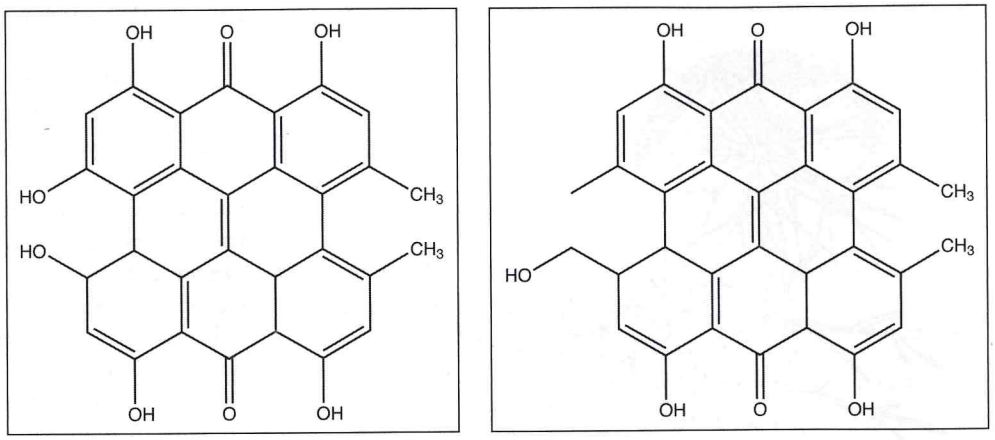

Figure 3. Hypericin (left) and pseudohypericin (right).

A similar trial of 87 patients, again with some post-BCG or radiotherapy, also used 40 mL of an 8-μM solution of hypericin instilled into the bladder for 2 hours.[29] There were 11 false-positive biopsies, 7 of which occurred in patients exposed to BCG within the past 2 months. Overall sensitivity was 94%, and specificity was 95%. There was no photobleaching. Hypericin was shown to localize to the epithelium, in a manner similar to that of 5-ALA, which limits systemic toxicity potential.

This correlates well with another human trial showing undetectable hypericin levels after bladder instillation of a solution identical to those just discussed.[30] There were no adverse effects. The researchers suggested that patients should be at least 4 months past BCG therapy before using this technique to assess efficacy.

Rodent studies have shown that 1–5 mg/kg of hypericin given i.v., then followed 30 minutes later by bladder phototherapy results in significant inhibition of bladder cancer.[31] Waiting any longer than this to illuminate the bladder tumors greatly reduced efficacy. Intravesical administration of a 30-μM of hypericin solution for 2 hours in rat bladders with implanted transitional-cell carcinoma followed by 595-nm laser illumination resulted in killing of 95%–98% of bladder-cancer cells, although there was regrowth within 3 weeks.[32] The researchers concluded this was, in part, the result of insufficient oxygen in the tissue for total cell killing.

In a very similar model, intravesical hypericin was shown to accumulate preferentially in bladder-cancer cells (12:1, compared to healthy epithelium) with no accumulation in healthy submucosa or muscle tissue.[33] A separate rat trial found that adding the oxygen-carrying synthetic compound perfluorodecalin greatly enhanced the anticancer activity of hypericin in bladder-cancer cells.[34] Unfortunately no human trials have been published on whether or not intravesical hypericin is effective for bladder cancer in a clinical setting.

However, clinical trials of photodynamic therapy with hypericin for other cancers have been reported. In a group of 34 white men and women with actinic keratosis, basal-cell carcinoma (BCC), or Bowen's disease, a concentrated crude extract of St. John's wort standardized to 2 mg/mL of hypericin was applied to the lesions after removing any obvious obscuring squamous tissue and 10 mm of surrounding skin in a 1-mm thick layer then covered with a dressing for 2 hours.[35] Then the areas were exposed to a red light lamp (580–680 nm) for 15–20 minutes at 75 J/cm^2. This was repeated once per week for at least 6 weeks in all patients. Half of the patients with actinic keratosis had complete clinical remission at 3 months, and 30% of the patients had complete clinical remission at 6 months. Just 10% of superficial BCCs were completely cleared by histologic assessment, and none of the nodular BCCs were cleared. Fully 80% of patients with Bowen's disease had complete histologic clearance. Most patients reported burning at the site of treatment, which was readily treated by turning on a fan and directing it toward the site. No other adverse effects occurred.

In another clinical trial, involving 8 patients with squamous-cell carcinoma (SCC), hypericin was injected into the lesions at a dose of 40–100 mcg 3–5 times per week for 2–4 weeks.[36] In the same trial, 11 patients with BCC had intralesional injections of 40–200 mcg of hypericin 3–5 times per week for 2–6 weeks. After injection, the lesions were exposed to visible light. Clinical remission was apparently seen in all cases, although full details of the trial could not be obtained. Higher concentrations injected were more effective.

Twelve patients with cutaneous T-cell lymphoma (CTCL) and 11 patients with psoriasis had different lesions on their bodies treated with hypericin ointment (0.05%–0.25% concentration), hypericin in aqueous dimethyl sulfoxide (DMSO; 6 patients with psoriasis), or placebo topically twice per week in another clinical trial.[37] Each area was covered for 24 hours after treatment then exposed to visible light (590–650 nm, 5 J/cm^2) for 15 minutes. The light dose was increased by 1 J/cm^2 per week until phototoxicity occurred. There was a reduction in lesion size by 50% or more in 7/12 patients with CTCL after 6 weeks. There was a reduction in lesions by at least 50% in 55% of the patients with psoriasis (80% using the liquid hypericin in DMSO and 33% using the ointment). There were no responses to placebo in either group. Thus, the topical treatments were statistically and clinically significantly more effective than placebo in patients with both conditions. The 0.25%-hypericin ointment (or liquid in the case

Ammi visnaga (khella). Drawing © 2012 by Eric Yarnell, ND, RH (AHG).

of psoriasis) was clearly most effective at light doses of 8–20 J/cm^2. Mild erythema, burning, and pruritus were common at sites of application.

In patients with glioblastomas or anaplastic astrocytomas that recurred after radiation therapy (and sometimes after chemotherapy), a dose-finding study was conducted that found that 0.2 mg/kg daily was a safe initial dose.[38] If no adverse effects occurred after 14 days on this dose, then it was increased slowly up to as high as 0.5 mg/kg daily. A total of 17 patients completed 3 months of treatment, and 12 continued treatment beyond that time.

The mean maximal tolerated dose was 0.4 mg/kg. Fully 74% of the total 42 patients in the trial ultimately had adverse effects related to hypericin, mainly, photosensitivity rash (43%), erythema (26%), and a burning sensation in the skin (14%). None of these reactions was severe enough for hospitalization. A total of 24% of patients had digestive adverse effects possibly caused by hypericin. Neurologic symptoms were common but most likely resulted from disease progression and not hypericin. Of the total 42 patients in the study, 22% achieved stable disease or a partial response (> 50% tumor shrinkage). Of those 17 patients who survived to complete 3 months of therapy, 53% achieved stable disease or a partial response. This corresponds to a 40% 3-month survival rate. Eight patients survived > 6 months.

No other clinical trials of the use of hypericin to treat gliomas have been attempted as these were limited by the difficulty of getting visible light to the tumors directly. Hypericin in the blood may be activated by light exposure through the skin as the hypericin circulates in the blood. One study has found that giving i.v. hypericin before surgery to remove glioma tissue greatly enhances visualization of the cancerous brain tissue and the ability to distinguish it from healthy brain tissue.[39] Uptake of hypericin in vitro in glioma tissue removed from patients with high-grade disease was correlated with a good prognosis in another trial.[40] Temozolomide and diazepam may enhance the antiglioma effects of hypericin according to preclinical studies.[41,42]

Preclinical work has also shown that simple hypericin solutions can be applied to photodiagnosis and phototherapy of gastric cancer, with greater sensitivity, specificity and safety than 5-ALA, an agent currently used for these purposes.[43] Hyperoxygenation and hyperthermia augmented the activity of hypericin against gastric cancer. Esophageal-cancer cells may also be susceptible to hypericin photodynamic therapy.[44]

In an open trial, patients with wet or neovascular macular degeneration (a total of 34 affected eyes involved) were treated with an oral St. John's wort extract (1.8 g q.d., 0.3% hypericin content) by mouth then treated with 24 J/cm^2 of laser 4 hours later.[45] Maintenance therapy with 600 mg St. John's wort was continued for 6 months. Depending on the subtype of the condition, 71%–80% of the treated eyes were resolved anatomically with 6 months of follow-up, but clinical resolution occurred in only 14%–20% of eyes. There was one case of severe gastric upset and two of pigment epithelial rupture. A controlled trial is recommended to follow-up on these results.

St. John's wort extracts and hypericins show enormous promise for diagnosis and treatment of many conditions. More research is warranted, but, for some applications, given the safety of these medicines, their use is appropriate now. This is particularly true in patients with advanced cancer with a poor prognosis.

Citrus

Ruta graveolens (rue) and *R. chalepensis* (fringed rue) are Eurasian native plants in the Rutaceae (citrus) family that contain photosensitizing furanocoumarins. Quite a few cases of photosensitivity dermatitis have been reported as a result of the use of various species of rue.[46–48] Fringed rue has been shown to have inflammation-modulating activity in line with its traditional uses.[49] In vitro, these compounds have been shown to be antineoplastic by inhibiting topoisomerase I.[50] Historical records from ancient times do not report any topical use of rue as a photosensitizer, although it was used topically to treat wounds.[51] Synthetic versions of rue furanocoumarins are in development for treatment of autoimmune diseases.[52]

Many Rutaceae species, including rue, contain bergapten (see Fig. 2).[53] Various species of *Citrus*, including lemon (*Citrus* x *limon*), bitter orange (*Citrus* x *aurantium*), lime (*Citrus* x *aurantifolia*), and pomelo (*Citrus maxima*), have been used in European and Chinese medicine for centuries.[54] Grapefruit (*Citrus* x *paradisi*) also contains photosensitive furanocoumarins, which have also been shown to be intestinal cytochrome 3A4 (CYP3A4) inhibitors. At least one case study shows that grapefruit can be used to assist the treatment of advanced psoriasis by increasing absorption of cyclosporin (a CYP3A4 substrate), but raises the additional potential that grapefruit may be photosensitizing in this kind of situation.[55] This hypothesis remains to be confirmed.

In vitro, mandarin orange (*Citrus reticulata*) or *chen pi*, a major Chinese medicine, has been shown to have potential for treating vitiligo, although this appeared to be through stimulation of healthy melanocyte proliferation.[56] *Citrus* x *hystrix* (kaffir lime) from Malaysia had photodynamic activity against human leukemia in vitro.[57]

Much work remains to be done to determine if any Rutaceae family plants have clinical applications as useful photosensitizing agents. In the meantime caution is warranted to avoid causing photodermatitis in patients using citrus species for other reasons.

Conclusion

Numerous plants show promise as photosensitizers, as adjuncts to UV or visible light therapy and for photodiagnosis of some conditions. Furanocoumarin-containing plants such as *Ammi* spp. have been best studied as adjuncts to UV therapy for psoriasis and vitiligo. *Hypericum perforatum* and its hypericins have been extensively studied for diagnosis of precancerous and cancerous lesions in many areas of the body as well as for therapy of these and some other conditions including macular degeneration. Overall, these approaches need further assessment but have been quite safe, particularly, compared to existing synthetic photosensitizers. ■

References

1. Pustisek N, Situm M. UV-radiation, apoptosis and skin. Coll Antropol 2011;35(suppl2):339–341.

2. el Mofty AM. A preliminary clinical report on the treatment of leukoderma with *Ammi majus* Linn. J R Egypt Med Assn 1948,31:651–665.

3. McKenna WB. *Ammi majus* Linn in the treatment of vitiligo. Scott Med J 1957;2:69–70.

4. Oszast Z, Krasowska H. First experimental application of *Ammi majus* L extract prepared in Poland, in the treatment of vitiligo [in Polish]. Przegl Dermatol 1957;7:1–14.

5. Venkateswaran CH. Treatment of vitiligo with extracts of *Ammi majus* Linn. J Indian Med Assoc 1955;24:618–620.

6. Selim YA, Ouf NH. Anti-inflammatory new coumarin from the *Ammi majus* L. *Org* Med Chem Lett 2012;2:1.

7. Koriem KM, Asaad GF, Megahed HA, et al. Evaluation of the antihyperlipidemic, anti-inflammatory, analgesic, and antipyretic activities of ethanolic extract of *Ammi majus* seeds in albino rats and mice. Int J Toxicol 2012; 31:294–300.

8. Singab AN. Acetylated flavonol triglycosides from *Ammi majus* L. Phytochemistry 1998;49:2177–2180.

9. Ossenkoppele PM, van der Sluis WG, van Vloten WA. Phototoxic dermatitis following the use of *Ammi majus* fruit for vitiligo [in Dutch]. Ned Tijdschr Geneeskd 1991;135:478–480.

10. Weiss R. Herbal Medicine, classic ed. Stuttgart: Thieme, 1985.

11. Abdel-Fattah A, Aboul-Enein MN, Wassel G, El-Menshawi B. Preliminary report on the therapeutic effect of khellin in psoriasis. Dermatologica 1983;167:109–110.

12. Abdel-Fattah A, Aboul-Enein MN, Wassel GM, El-Menshawi BS. An approach to the treatment of vitiligo by khellin. Dermatologica 1982;165:136–140.

13. de Leeuw J, van der Beek N, Maierhofer G, Neugebauer WD. A case study to evaluate the treatment of vitiligo with khellin encapsulated in L-phenylalanin stabilized phosphatidylcholine liposomes in combination with ultraviolet light therapy. Eur J Dermatol 2003;13:474–477.

14. Orecchia G, Perfetti L. Photochemotherapy with topical khellin and sunlight in vitiligo. Dermatology 1992;184:120–123.

15. Vedaldi D, Caffieri S, Dall'Acqua F, et al. Khellin, a naturally occurring furochromone, used for the photochemotherapy of skin diseases: Mechanism of action. Farmaco Sci 1988;43:333–346.

16. Morliere P, Hönigsmann H, Averbeck D, et al. Phototherapeutic, photobiologic, and photosensitizing properties of khellin. J Invest Dermatol 1988; 90:720–724.

17. el Mofty AM, el Sawalhy H, el Mofty M. Clinical study of a new preparation of 8-methoxypsoralen in photochemotherapy. Int J Dermatol 1994;8:588–592.

18. Lagey K, Duinslaeger L, Vanderkelen A. Burns induced by plants. Burns 1995;21:542–543.

19. Moore M. Cow parsnip. In: Medicinal Plants of the Pacific West. Santa Fe: Red Crane Books, 1993:167—171.

20. Skalkos D, Gioti E, Stalikas CD, et al. Photophysical properties of *Hypericum perforatum* L. extracts—novel photosensitizers for PDT. J Photochem Photobiol B 2006;82:146–151.

21. Jacobson JM, Feinman L, Liebes L, et al. Pharmacokinetics, safety, and antiviral effects of hypericin, a derivative of St. John's wort plant, in patients with chronic hepatitis C virus infection. Antimicrobial Agents Chemother 2001;45:517–524.

22. Gulick R, Lui H, Anderson R, et al. Human hypericism: A photosensitivity reaction to hypericin (St. John's wort). Int Conf AIDS 1992;8:B90:abstract #PoB 3018.

23. Schulz HU, Schurer M, Bassler D, Weiser D. Investigation of the effect on photosensitivity following multiple oral dosing of two different hypericum extracts in healthy men. Arzneim Forsch 2006;56:212–221.

24. Brockmöller J, Reum T, Bauer S, et al. Hypericin and pseudohypericin: Pharmacokinetics and effects on photosensitivity in humans. Pharmacopsychiatry 1997;30(suppl2):94–101.

25. Kapsokalyvas D, Dimitriou H, Skalkos D, et al. Does *Hypericum perforatum* L extract show any specificity as photosensitizer for HL-60 leukemic cells and cord blood hemopoietic progenitors during photodynamic therapy? J Photochem Photobiol B 2005;80:208–216.

26. Skalkos D, Stavropoulos NE, Tsimaris I, et al. The lipophilic extract of *Hypericum perforatum* exerts significant cytotoxic activity against T24 and NBT-II urinary bladder tumor cells. Planta Med 2005;71:1030–1035.

27. D'Hallewin MA, De Witte PA, Waelkens E, et al. Fluorescence detection of flat bladder carcinoma in situ after intravesical instillation of hypericin. J Urol 2000;164:349–351.

28. Van de Putte M, Ni Y, De Witte PA. Exploration of the mechanism underlying the tumor necrosis avidity of hypericin. Oncol Rep 2008;19:921–926.

29. D'Hallewin MA, Kamuhabwa AR, Roskams T, et al. Hypericin-based fluorescence diagnosis of bladder carcinoma. BJU Int 2002;89:760–763.

30. Kamuhabwa AA, Di Mavungu JD, Baert L, et al. Determination of hypericin in human plasma by high-performance liquid chromatography after intravesical administration in patients with transitional cell carcinoma of the bladder. Eur J Pharm Biopharm 2005;59:469–474.

31. Zupkó I, Kamuhabwa AR, D'Hallewin MA, et al. In vivo photodynamic activity of hypericin in transitional cell carcinoma bladder tumors. Int J Oncol 2001;18:1099–1105.

32. Kamuhabwa AA, Roskams T, D'Hallewin MA, et al. Whole bladder wall photodynamic therapy of transitional cell carcinoma rat bladder tumors using intravesically administered hypericin. Int J Cancer 2003;107:460–467.

33. Kamuhabwa AA, Cosserat-Gerardin I, Didelon J, et al. Biodistribution of hypericin in orthotopic transitional cell carcinoma bladder tumors: Implication for whole bladder wall photodynamic therapy. Int J Cancer 2002;97:253–260.

34. Kamuhabwa AR, Huygens A, Roskams T, De Witte PA. Enhancing the photodynamic effect of hypericin in human bladder transitional cell carcinoma spheroids by the use of the oxygen carrier, perfluorodecalin. Int J Oncol 2006;28:775–780.

35. Kacerovská D, Pizinger K, Majer F, Smíd F. Photodynamic therapy of nonmelanoma skin cancer with topical *Hypericum perforatum* extract—a pilot study. Photochem Photobiol 2008;84:779–785.

36. Alecu M, Ursaciuc C, Halalau F, et al. Photodynamic treatment of basal cell carcinoma and squamous cell carcinoma with hypericin. Anticancer Res 1998;18(6B):4651–4654.

37. Rook AH, Wood GS, Duvic M, et al. A phase II placebo-controlled study of photodynamic therapy with topical hypericin and visible light irradiation in the treatment of cutaneous T-cell lymphoma and psoriasis. J Am Acad Dermatol 2010;63:984–990.

38. Couldwell WT, Surnock AA, Tobia AJ, et al. A phase 1/2 study of orally administered synthetic hypericin for treatment of recurrent malignant gliomas. Cancer 2011;117:4905–4915.

39. Ritz R, Daniels R, Noell S, et al. Hypericin for visualization of high grade gliomas: First clinical experience. Eur J Surg Oncol 2012;38:352–360.

40. Ritz R, Müller M, Dietz K, et al. Hypericin uptake: A prognostic marker for survival in high-grade glioma. J Clin Neurosci 2008;15:778–783.

41. Gupta V, Su YS, Wang W, et al. Enhancement of glioblastoma cell killing by combination treatment with temozolomide and tamoxifen or hypericin. Neurosurg Focus 2006;20:E20.

42. Sarissky M, Lavicka J, Kocanová S, et al. Diazepam enhances hypericin-induced photocytotoxicity and apoptosis in human glioblastoma cells. Neoplasma 2005;52:352–359.

43. Saw CL, Heng PW, Olivo M. Potentiation of the photodynamic action of hypericin. J Environ Pathol Toxicol Oncol 2008;27:23–33.

44. Höpfner M, Maaser K, Theiss A, et al. Hypericin activated by an incoherent light source has photodynamic effects on esophageal cancer cells. Int J Colorectal Dis 2003;18:239–247.

45. Sobaci G, Bayraktar MZ, Karslioglu Y, et al. Hypericin-enhanced argon laser photocoagulation for subfoveal choroidal neovascular membrane in age-related macular degeneration: A pilot study. Eur J Ophthalmol 2006;16:119–128.

46. Arias-Santiago SA, Fernández-Pugnaire MA, Almazán-Fernández FM, et al. Phytophotodermatitis due to *Ruta graveolens* prescribed for fibromyalgia. Rheumatology (Oxford) 2009;48:1401.

47. Wessner D, Hofmann H, Ring J. Phytophotodermatitis due to *Ruta graveolens* applied as protection against evil spells. *Contact Dermatitis* 1999;41:232.

48. Brener S, Friedman J. Phytophotodermatitis induced by *Ruta chalepensis* L. Contact Dermatitis 1985;12:230–232.

49. al-Said MS, Tariq M, al-Yahya MA, et al. Studies on *Ruta chalepensis*, an ancient medicinal herb still used in traditional medicine. J Ethnopharmacol 1990;28:305–312.

50. Diwan R, Malpathak N. Furanocoumarins: Novel topoisomerase I inhibitors from *Ruta graveolens* L. Bioorg Med Chem 2009;17:7052–7055.

51. Pollio A, De Natale A, Appetiti E, Aliotta G, Touwaide A. Continuity and change in the Mediterranean medical tradition: *Ruta* spp. (rutaceae) in Hippocratic medicine and present practices. J Ethnopharmacol 2008;116:469–482.

52. Bodendiek SB, Mahieux C, Hänsel W, Wulff H. 4-Phenoxybutoxy-substituted heterocycles—a structure–activity relationship study of blockers of the lymphocyte potassium channel Kv1.3. Eur J Med Chem 2009;44:1838–1852.

53. Chen Z, Lin L. Study on coumarin compounds from *Exocarpium Citri Grandis* [in Chinese]. Zhong Yao Cai 2004;27:577–578.

54. Arias BA, Ramón-Laca L. Pharmacological properties of citrus and their ancient and medieval uses in the Mediterranean region. J Ethnopharmacol 2005;97:89–95.

55. Taniguchi S, Kobayashi H, Ishii M. Treatment of psoriasis by cyclosporine and grapefruit juice. Arch Dermatol 1996;132:1249.

56. Lin ZX, Hoult JR, Raman A. Sulphorhodamine B assay for measuring proliferation of a pigmented melanocyte cell line and its application to the evaluation of crude drugs used in the treatment of vitiligo. J Ethnopharmacol 1999;66:141–150.

57. Ong CY, Ling SK, Ali RM, et al. Systematic analysis of in vitro photocytotoxic activity in extracts from terrestrial plants in Peninsula Malaysia for photodynamic therapy. J Photochem Photobiol B 2009;96:216–222.

Eric Yarnell, ND, RH (AHG), is chief medical officer of Northwest Naturopathic Urology, in Seattle, Washington, and is a faculty member at Bastyr University in Kenmore, Washington. **Kathy Abascal, BS, JD, RH (AHG),** is executive director of the Botanical Medicine Academy in Vashon, Washington.
